

Editor

Roger J Hall

Commissioning Editor

Iain Simpson

Associate Editors

Adrian P Banning, Martin Cowie, Filippo Crea, David Crossman, John L Gibbs, Bernard Jung, Andreas Mügge

US Associate Editor

Catherine M Otto
(Washington)

JournalScan Editor

Iqbal S Malik

Statistical Advisor

Ian Ford

Deputy Editor

David Lefroy

Series Editor, Education in Heart

Peter Mills

Managing Editor

Janet O'Flaherty

Technical Editor

John Weller

Editorial Assistants

Ian Betteridge
Stephanie Watkins

International Advisory Board

Gianni de Angelini (UK)
Fause Attie (Mexico)
Philip E G Aylward (Australia)
George A Beller (USA)
Martin R Bennett (UK)
Nicholas A Boon (UK)
Roger M Boyle (UK)
Paulo G Camici (UK)
Terry Campbell (Australia)
Alfred Cheng (Singapore)
Stuart M Cobbe (UK)
Lawrence S Cohen (USA)
David C Crossman (UK)
Nicolas Danchin (France)
Henry J Dargie (UK)
Mark A de Belder (UK)
Pim J de Feyter (Netherlands)
Carlo di Mario (Italy)
Jean-Noel Fabiani (France)
Roberto Ferrari (Italy)
Peter J Fitzgerald (USA)
Keith A A Fox (UK)
D S Gambhir (India)
Clifford J Garratt (UK)
Marc H Gewillig (Belgium)
Sally Greaves (New Zealand)
Jorgen Fischer Hansen (Denmark)
Axel Haverich (Germany)
Otto M Hess (Switzerland)
Gerd Heusch (Germany)
Pierre Jaïs (France)
Jean Kachaner (France)
Sanjiv Kaul (USA)
Bruce Keogh (UK)
Robert A Kloner (USA)
Cornelius Klutt (Netherlands)
Michael Komajda (France)
S Krishnaswami (India)

C C Lang (Malaysia)
Herve LeMarec (France)
Janet M McComb (UK)
Bernard Meier (Switzerland)
R Gordon Murray (UK)
Catherine M Otto (USA)
Dudley J Pennell (UK)
Shabbudin H Rahimtoolah (USA)
John Sanderson (Hong Kong)
Maurice E Sarano (USA)
Pinchas Sareli (South Africa)
James Scott (UK)
Ajay M Shah (UK)
Man Fai Shiu (UK)
Jordi Soler-Soler (Spain)
Giuseppe Specchia (Italy)
Martin St John Sutton (USA)
William G Stevenson (USA)
Kenneth M Taylor (UK)
Adam D Timmis (UK)
James D Thomas (USA)
Eric Topol (USA)
Dimitris Tousoulis (Greece)
Pavlos K Toutouzas (Greece)
Alec Vahanian (France)
Cees A Visser (Netherlands)
Ludwig K von Segesser (Switzerland)
Carole A Warnes (USA)
Hugh Watkins (UK)
Gary Webb (Canada)
Sylvan Lee Weinberg (USA)
Harvey D White (New Zealand)
Peter Wilde (UK)
Neil Wilson (UK)
Junichi Yoshikawa (Japan)
Editor: *British Medical Journal*
Editor Emeritus: Michael J Davies

Instructions to authors

Full instructions are available online at www.heartjnl.com/misc/ifora.shtml

If you do not have web access please contact the editorial office:
Heart

9 Fitzroy Square
London W1T 5HW, UK
Telephone +44 (0) 20 7383 4006
Fax +44 (0) 20 7388 0323
Email heartjournal@bmjgroup.com

Subscription information

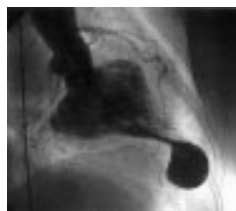
See page ii

Copyright

© 2003 BMJ Publishing Group and British Cardiac Society. All rights reserved; no part of this publication may be reproduced, stored in a retrieval system, or transmitted in any form or by any means, electronic, mechanical, photocopying, recording, or otherwise without prior permission

Authors are required to grant *Heart* an exclusive licence to publish; further details available online at www.heartjnl.com/misc/ifora.shtml

- *Heart* is published by BMJ Publishing Group and printed in UK on acid free paper by Stephens and George Magazines Limited, Merthyr Tydfil
- Periodicals postage paid, Rahway, NJ. Postmaster: send address changes to: *Heart*, c/o Mercury Airfreight International Ltd, 365 Blair Road, Avenel, NJ 07001, USA



See p 178



www.publicationethics.org.uk

This journal is a member of and subscribes to the principles of the Committee on Publication Ethics

Editorials

- 121 Cardiovascular effects of testosterone: implications of the "male menopause"?
K S Channer, T H Jones
- 123 Syncope: what is the trigger? *R Hainsworth*
- 125 Exercise blood pressure in congenital heart disease and in patients after coarctation repair
M Hauser

Viewpoint

- 127 Drug eluting stents: maximising benefit and minimising cost *J Gunn, A C Morton, C Wales, C M H Newman, D C Crossman, D C Cumberland*

Review

- 133 Drug eluting stents: are human and animal studies comparable? *R Virmani, F D Kolodgie, A Farb, A Lafont*

Cardiovascular medicine

- 139 Myocardial contrast echocardiography is superior to other known modalities for assessing myocardial reperfusion after acute myocardial infarction *K Greaves, S R Dixon, M Fejka, W W O'Neill, S R Redwood, M S Marber, R Senior*
- 145 Assessment of myocardial perfusion abnormalities by intravenous myocardial contrast echocardiography with harmonic power Doppler imaging: comparison with positron emission tomography *T Muro, T Hozumi, H Watanabe, H Yamagishi, M Yoshiyama, K Takeuchi, J Yoshikawa*
- 150 NT-proBNP: a new diagnostic screening tool to differentiate between patients with normal and reduced left ventricular systolic function *M Bay, V Kirk, J Parner, C Hassager, H Nielsen, K Krogsgaard, J Trawinski, S Boesgaard, J Aldershvile*
- 155 Comprehensive cardiac rehabilitation programme for implantable cardioverter defibrillator patients: a randomised controlled trial *A Fitchet, P J Doherty, C Bundy, W Bell, A P Fitzpatrick, C J Garratt*
- 161 Mitral annular calcification: a marker of severe coronary artery disease in patients under 65 years old *S Atar, D S Jeon, H Luo, R J Siegel*
- 165 Atrial fibrillation: relation between clinical risk factors and transoesophageal echocardiographic risk factors for thromboembolism *S Illien, S Maroto-Järvinen, G von der Recke, C Hammerstingl, H Schmidt, S Kuntz-Hehner, B Lüderitz, H Omran*
- 169 Abnormal response to sodium channel blockers in patients with Brugada syndrome: augmented localised wall motion abnormalities in the right ventricular outflow tract region detected by electron beam computed tomography *M Takagi, N Aihara, S Kuribayashi, A Taguchi, T Kurita, K Suyama, S Kamakura, M Takamiya*
- 175 Rarefaction of skin capillaries in normotensive offspring of individuals with essential hypertension *T F T Antonios, F M Rattray, D R J Singer, N D Markandu, P S Mortimer, G A MacGregor*

Interventional cardiology and surgery

- 179 Myocardial viability, coronary flow reserve, and in-hospital predictors of late recovery of contractility following successful primary stenting for acute myocardial infarction *F Beygui, C Le Feuvre, G Helft, C Maunoury, J P Metzger*
- 184 Coronary stenting versus coronary bypass surgery in patients with multiple vessel disease and significant proximal LAD stenosis: results from the ERACI II study *A Rodriguez, M Rodríguez Alemparte, J Baldi, J Navia, A Delacasa, D Vogel, R Oliveri, C Fernández Pereira, V Bernardi, W O'Neill, I F Palacios*

Congenital heart disease

- 189 Exercise systolic blood pressures are of questionable value in the assessment of the adult with a previous coarctation repair *L Swan, S Goyal, C Hsia, S Hechter, G Webb, M A Gatzoulis*
- 193 Fontan conversion to total cavopulmonary connection and arrhythmia ablation: clinical and functional results *G Agnoletti, A Borghi, G Vignati, G C Crupi*
- 199 Experience with transcatheter closure of secundum atrial septal defects using the Amplatzer septal occluder: a single centre study in 236 consecutive patients *G Fischer, J Stieh, A Uebing, U Hoffmann, G Morf, H H Kramer*

Scientific letters

- 205 Heart rate variability in children with hypertrophic cardiomyopathy *G Butera, D Bonnet, J Kachaner, D Sidi, E Villain*
- 207 Decreased serum vascular endothelial growth factor concentrations in patients with congestive heart failure *H Arakawa, U Ikeda, Y Hojo, S Ueno, M Nonaka-Sarukawa, K Yamamoto, K Shimada*
- 209 Prolonged temporary cardiac pacing using subcutaneous tunnelled active-fixation permanent pacing leads *N Lever, J D Ferguson, Y Bashir, K M Channon*
- 211 Enhanced endothelin-1 degradation by intravenous morphine in patients with congestive heart failure: role of neutral endopeptidase 24.11 *T-L Wang, C-R Hung*
- 213 Deletion polymorphism of the angiotensin I converting enzyme gene is a potent risk factor for coronary artery ectasia *S Gülec, Ö Aras, Y Atmaca, Ö Akyürek, N Q Hanson, T Sayin, M Y Tsai, N Akar, D Oral*
- 215 Asymptomatic ventricular pre-excitation in children and adolescents: a 15 year follow up study *B Sarubbi, G Scognamiglio, G Limongelli, B Mercurio, G Pacileo, C Pisacane, M G Russo, R Calabrò*

Education in Heart

- 218 In-stent stenosis: pathology and implications for the development of drug eluting stents *M R Bennett*
- 225 Chronic cor pulmonale *E Weitzenblum*
- 231 Clinical assessment of left ventricular diastolic function *D G Gibson, D P Francis*

JournalScan

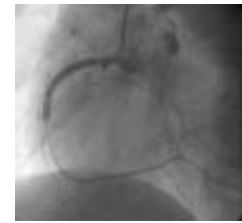- 239 Cardiovascular highlights from non-cardiology journals

Electronic pages

- e5 Acute thrombosis of the sinus node artery: arrhythmological implications *G Ando', A Gaspardone, I Proietti*
- e6 Intrastent sonotherapy in pulmonary vein restenosis: a new treatment for a recalcitrant problem *C J McMahon, C E Mullins, H G El Said*
- e7 Protein C deficiency manifesting as an acute myocardial infarction and ischaemic stroke *I Y Tiong, M L Alkotob, S Ghaffari*
- e8 Obstructive intramural coronary amyloidosis and papillary muscle rupture *D Coisne, P Corbi, P Sosner*

Miscellanea

- 122 Images in cardiology: Cystic tumour of the atrioventricular node *Y Nojima, H Ishibashi-Ueda, M Yamagishi*
- 124 From BMJ Journals: Prophylactic indomethacin can harm very low birthweight babies with severe CHD
- 131 Images in cardiology: A giant thrombus aspirated from a coronary artery *T Miyamoto, T Sasaki, A Niwa*
- 132 Images in cardiology: In-stent restenosis and atherosclerosis in a human saphenous vein graft *N J Alp, J Gunn, K M Channon*
- 132 Images in cardiology: Anomalous right coronary artery originating from the mid left main coronary artery *T Chatterjee, P Erne*
- 138 Images in cardiology: Huge mass bordering on left atrium raises coronary artery *H Okamura, K Bando, M Higashi*
- 138 Images in cardiology: Acute left ventricular rupture after myocardial infarction *P L Sanchez*
- 149 From BMJ Journals: Lipoprotein (a) is not part of the acute phase response
- 164 Images in cardiology: Spontaneous coronary artery dissection: stent it or wait for healing? *R Sarmento-Leite, P R M Machado, S L Garcia*
- 168 Electronic pages
- 178 Images in cardiology: Sudden cardiac death caused by hypertrophic cardiomyopathy associated with midventricular obstruction and apical aneurysm *H-F Tse, H-H Ho*
- 198 Images in cardiology: Vasospastic angina *V Suresh, R Levy*
- 208 Web Top 10
- 210 Electronic pages



See p 198