

## Editor

Roger J Hall

## Commissioning Editor

Iain Simpson

## Associate Editors

Adrian P Banning, Alain Berrebi, Eric Butchart, Filippo Crea, David Crossman, John L Gibbs, Bernard Lung, Andreas Mügge

## US Associate Editor

Catherine M Otto  
(Washington)

## JournalScan Editor

Iqbal S Malik

## Statistical Advisor

Ian Ford

## Deputy Editor

David Lefroy

## Series Editor, Education in Heart

Peter Mills

## Managing Editor

Janet O'Flaherty

## Technical Editor

John Weller

## Editorial Assistants

Andy Fosberry  
Stephanie Watkins

## International Advisory Board

Gianni de Angelini (UK)  
Fause Attie (Mexico)  
Philip E G Aylward (Australia)  
Gary Baxter (UK)  
George A Beller (USA)  
Martin R Bennett (UK)  
Nicholas A Boon (UK)  
Roger M Boyle (UK)  
Paulo G Camici (UK)  
Terry Campbell (Australia)  
Alfred Cheng (Singapore)  
Stuart M Cobbe (UK)  
Lawrence S Cohen (USA)  
Martin Cowie (UK)  
Nicolas Danchin (France)  
Henry J Dargie (UK)  
Mark A de Belder (UK)  
Pim J de Feyter (Netherlands)  
Carlo di Mario (Italy)  
Jean-Noel Fabiani (France)  
Roberto Ferrari (Italy)  
Peter J Fitzgerald (USA)  
Keith A A Fox (UK)  
D S Gambhir (India)  
Clifford J Garratt (UK)  
Marc H Gewillig (Belgium)  
Sally Greaves (New Zealand)  
Jorgen Fischer Hansen (Denmark)  
Axel Haverich (Germany)  
Otto M Hess (Switzerland)  
Gerd Heusch (Germany)  
Pierre Jaïs (France)  
Jean Kachaner (France)  
Sanjiv Kaul (USA)  
Bruce Keogh (UK)  
Robert A Kloner (USA)  
Cornelius Klufft (Netherlands)

Michael Komajda (France)  
S Krishnaswami (India)  
C C Lang (Malaysia)  
Herve LeMarec (France)  
Janet M McComb (UK)  
Bernard Meier (Switzerland)  
R Gordon Murray (UK)  
Catherine M Otto (USA)  
Dudley J Pennell (UK)  
Shahbudin H Rahimtoolah (USA)  
John Sanderson (Hong Kong)  
Maurice E Sarano (USA)  
Pinchas Sareli (South Africa)  
James Scott (UK)  
Ajay M Shah (UK)  
Man Fai Shiu (UK)  
Jordi Soler-Soler (Spain)  
Giuseppe Specchia (Italy)  
Martin St John Sutton (USA)  
William G Stevenson (USA)  
Kenneth M Taylor (UK)  
Adam D Timmis (UK)  
James D Thomas (USA)  
Eric Topol (USA)  
Dimitris Tousoulis (Greece)  
Pavlos K Toutouzas (Greece)  
Alec Vahanian (France)  
Cees A Visser (Netherlands)  
Ludwig K von Segesser (Switzerland)  
Carole A Warnes (USA)  
Hugh Watkins (UK)  
Gary Webb (Canada)  
Sylvan Lee Weinberg (USA)  
Harvey D White (New Zealand)  
Neil Wilson (UK)  
Junichi Yoshikawa (Japan)  
Editor: *British Medical Journal*

## Instructions to authors

Full instructions are available online at [www.heartjnl.com/misc/ifora.shtml](http://www.heartjnl.com/misc/ifora.shtml)

If you do not have web access please contact the editorial office:

Heart  
9 Fitzroy Square  
London W1T 5HW, UK  
Telephone +44 (0) 20 7383 4006  
Fax +44 (0) 20 7388 0323  
Email [heartjournal@bmjgroup.com](mailto:heartjournal@bmjgroup.com)

## Subscription information

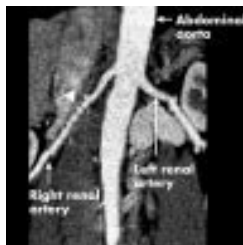

See page ii

## Copyright

© 2003 BMJ Publishing Group and British Cardiac Society. All rights reserved; no part of this publication may be reproduced, stored in a retrieval system, or transmitted in any form or by any means, electronic, mechanical, photocopying, recording, or otherwise without prior permission

Authors are required to grant *Heart* an exclusive licence to publish; further details available online at [www.heartjnl.com/misc/ifora.shtml](http://www.heartjnl.com/misc/ifora.shtml)

- *Heart* is published by BMJ Publishing Group and printed in UK on acid free paper by Stephens and George Magazines Limited, Merthyr Tydfil
- Periodicals postage paid, Rahway, NJ. Postmaster: send address changes to: *Heart*, c/o Mercury Airfreight International Ltd, 365 Blair Road, Avenel, NJ 07001, USA



See p 639

## Editorials

- 585 Heart failure: a global disease requiring a global response *J E Sanderson, T-F Tse*
- 587 Estimating prognosis in heart failure: time for a better approach *M R Cowie*
- 589 Drug treatment of hypertension: implications of ALLHAT *B Williams*
- 591 Non-invasive coronary imaging: computed tomography or magnetic resonance imaging? *C R Peebles*

## Viewpoint

- 595 Congenital coronary artery dilatation *S Chakraborti, E Thomas, J G C Wright, J J Vettukattil*

## Review

- 597 Microarray analysis: a novel research tool for cardiovascular scientists and physicians *C Napoli, L O Lerman, V Sica, A Lerman, G Tajana, F de Nigris*

## Cardiovascular medicine

- 605 Predicting mortality in patients with heart failure: a pragmatic approach *M L Bouvy, E R Heerdink, H G M Leufkens, A W Hoes*
- 610 Pattern of ventilation during exercise in chronic heart failure *K K A Witte, S D R Thackray, N P Nikitin, J G F Cleland, A L Clark*
- 615 Prognosis for patients newly admitted to hospital with heart failure: survival trends in 12 220 index admissions in Leicestershire 1993–2001 *H M Blackledge, J Tomlinson, I B Squire*
- 621 Different responses to dobutamine in the presence of carvedilol or metoprolol in patients with chronic heart failure *E Bollano, M Scharin Täng, Å Hjalmarson, F Waagstein, B Andersson*
- 625 Coronary calcifications in young patients with first, unheralded myocardial infarction: a risk factor matched analysis by electron beam tomography *K Pohle, D Ropers, R Mäffert, P Geitner, W Moshage, M Regenfus, M Kusus, W G Daniel, S Achenbach*
- 629 Comparative follow up of patients with implanted cardioverter-defibrillators after induction of sustained monomorphic ventricular tachycardias or ventricular fibrillation by programmed stimulation *M Meyborg, R Mura, C Tiefenbacher, R Becker, J Michaelsen, F Niroomand*
- 633 Non-invasive intravenous coronary angiography using electron beam tomography and multislice computed tomography *A W Leber, A Knez, C Becker, A Becker, C White, C Thilo, M Reiser, R Haberl, G Steinbeck*

## Interventional cardiology and surgery

- 640 Clinical and angiographic acute and follow up results of intracoronary  $\beta$  brachytherapy in saphenous vein bypass grafts: a subgroup analysis of the multicentre European registry of intraluminal coronary  $\beta$  brachytherapy (RENO) *T M Schiele, E Regar, S Silber, E Eckhout, D Baumgart, W Wijns, A Colombo, W Rutsch, D Meerkin, A Gershlick, R Bonan, P Urban, for the RENO Investigators*



[www.publicationethics.org.uk](http://www.publicationethics.org.uk)

This journal is a member of and subscribes to the principles of the Committee on Publication Ethics

## Congenital heart disease

- 645 Stenting of the ductus arteriosus and banding of the pulmonary arteries: basis for various surgical strategies in newborns with multiple left heart obstructive lesions *I Michel-Behnke, H Akintuerk, I Marquardt, M Mueller, J Thul, J Bauer, K J Hagel, J Kreuder, P Vogt, D Schranz*

## Basic research

- 651 Biocorrosion of magnesium alloys: a new principle in cardiovascular implant technology? *B Heublein, R Rohde, V Kaese, M Niemeyer, W Hartung, A Haverich*

## Scientific letters

- 657 Intramyocardial coronary flow characteristics in patients with hypertrophic cardiomyopathy: non-invasive assessment by transthoracic Doppler echocardiography *N Watanabe, T Akasaka, Y Yamaura, M Akiyama, S Kaji, Y Saito, K Yoshida*
- 659 Measurements of cardiac troponin T in patients with hypertrophic cardiomyopathy *Y Sato, R Taniguchi, K Nagai, T Makiyama, H Okada, T Yamada, A Matsumori, Y Takatsu*
- 661 Brain natriuretic peptide facilitates severity classification of stable chronic heart failure with left ventricular dysfunction *S Sakurai, H Adachi, A Hasegawa, H Hoshizaki, S Oshima, K Taniguchi, M Kurabayashi*
- 663 Adipocyte derived plasma protein, adiponectin, is associated with smoking status in patients with coronary artery disease *T Miyazaki, K Shimada, H Mokuno, H Daida*
- 665 Same day discharge following elective percutaneous coronary intervention in patients with stable angina *A P Banning, O J M Ormerod, K Channon, C J McKenna, W Orr, B Boulton, Y Bashir, J C Forfar*
- 667 The variation of plasma concentrations of a novel, adipocyte derived protein, adiponectin, in patients with acute myocardial infarction *S Kojima, T Funahashi, T Sakamoto, S Miyamoto, H Soejima, J Hokamaki, I Kajiwara, S Sugiyama, M Yoshimura, K Fujimoto, Y Miyao, H Suefuji, A Kitagawa, N Ouchi, S Kihara, Y Matsuzawa, H Ogawa*
- 669 Early detection of left ventricular dysfunction in patients with  $\beta$  thalassaemia major by dobutamine stress echocardiography *L Hui, M P Leung, S Y Ha, A K T Chau, Y F Cheung*
- 671 Role of exercise treadmill testing in the management of erectile dysfunction: a joint cardiovascular/erectile dysfunction clinic *H Solomon, J Man, E Martin, G Jackson*

## Education in Heart

- 673 Resuscitation *Richard Vincent*

- 681 Ethnic differences in cardiovascular disease *Nish Chaturvedi*
- 687 A rational basis for selection among drugs of the same class *Morris J Brown*

## JournalScan

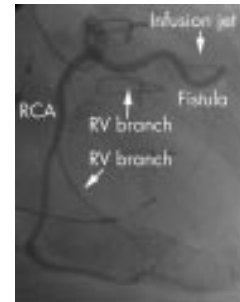
- 695 Cardiovascular highlights from non-cardiology journals

## Electronic pages

- e18 Novel use of an "insertable" loop recorder *J R Gimbel*
- e19 A 28 year old woman with ventricular tachycardia and an abnormal chest radiograph *M Heath, H Deubner, E J Stern, J E Cooke, E A Gill*

## Miscellanea

- 586 Images in cardiology: An unusual case of chest murmur demonstrated with three dimensional volume rendering with 16 row multislice spiral computed tomography *F Cademartiri, K Nieman, N Mollet*
- 588 Web Top 10
- 590 Electronic pages
- 594 Images in cardiology: Multiple coronary rupture after blunt chest trauma *K Dimopoulos, A Angelini, R Mencarelli, G Thiene*
- 604 Images in cardiology: A thermal view of the arterial wall after coronary angioplasty *L Diamantopoulos, X Liu, I De Scheerder*
- 639 Images in cardiology: Fibromuscular dysplasia in renovascular hypertension demonstrated by multislice CT: comparison with conventional angiogram and intravascular ultrasound *N Funabashi, N Komiyama, I Komuro*
- 644 Images in cardiology: Left ventricular microaneurysms as a cause of apparently idiopathic ventricular fibrillation *J Auer, R Berent, B Eber*
- 650 Images in cardiology: Thirty years after percutaneous closure of patent ductus arteriosus *A C Borges, V Glied, G Baumann*
- 656 Images in cardiology: Left main coronary artery fistula exiting into the right atrium *M Osraneck, C Warnes, J B Seward*
- 664 Images in cardiology: Coronary anomaly imaging by multislice computed tomography in corrected tetralogy of Fallot *K Nieman, J W Roos-Hesselink, P J de Feyter*
- 666 Images in cardiology: Valved conduit from the left ventricular apex to ascending aorta for recurrent congenital subaortic stenosis: 25 years later *E Kotschet, J Federman, B Davis*
- 696 Images in cardiology: Transoesophageal echocardiography of a large tricuspid valve vegetation: a perfect image of reality *I Gotsman, D Gilon, A Elami*



See p 664